

A Comparative Study on Surgical Correction of Prominent Ears in Children

HATEM EISAHAR, M.D.; AHMED M. SAMI, M.D. and HAMED M. KADRY, M.D.

The Department of Plastic & Reconstructive Surgery, Faculty of Medicine, Cairo University

ABSTRACT

Background: The prominent ear is the most common congenital deformity of the auricle. It is recommended for prominent ear to be surgically repaired before children start school.

Aim of Work: To perform a Study: On the surgical techniques used to correct the prominent ear deformity in children and its outcome as regards patient (parent) satisfaction.

Methods: Twenty cases of bilateral prominent ears were included in this study, equally divided into two groups, the first group was treated with concho-mastoid suture technique, while the second group was treated without concho-mastoid suture technique. The second group was further subdivided into two subgroups, in the first subgroup, prolene sutures were used in the surgical correction, while in the second subgroup PDS sutures were used in the surgical correction.

Results: It has been found that the concho-mastoid suture technique improves the cosmetic results and decreases the recurrence rate. Surgical correction using prolene sutures may be more liable to cause foreign body induced granuloma than surgical correction using PDS sutures, while surgical correction using PDS sutures may be more liable to cause cartilage necrosis, cosmetic disfigurement and recurrence than surgical correction using prolene sutures.

Key Words: Prominent ears – Bilateral – Concho-mastoid – Prolene – PDS.

INTRODUCTION

Congenital abnormalities of the auricle have been estimated to occur in 5% of the population [1]. The prominent ear is the most common congenital deformity of the auricle [2]. Since the original description of surgical correction of the prominent ear [3], an evolution in surgical techniques has occurred due to contributions of numerous surgeons.

The inheritance pattern of the prominent ear has been described as an autosomal dominant mode of transmission with incomplete penetrance. Potter reported that a dominant gene is involved based on a review of 92-member family tree of 5 generations with cupped and protruding ears [4].

A detailed understanding of auricular anatomy is necessary for a successful surgical outcome, the normal anatomy of the ear can be accurately understood by studying the topography of the auricle. Almost all the surface landmarks of the auricle are created by the shape of the underlying elastic cartilage. The ideal auricular position relative to other structures of the head contributes greatly to an aesthetically pleasing ear. The desired auriculo-cephalic angle is between 25-30 degree. The distance from the helical rim to the mastoid should be 15 to 20mm, both the auriculo-cephalic angle and helico-mastoid distance can be slightly greater in females than in males. Symmetric positioning, size and appearance of the ear are all important [5]. The ear reaches 85% of its adult size by 3 years of age and the normal ear is almost fully developed by the age of 6 years [6].

The prominent ear is a frequent deformity characterized by an increase of the cephalo-auricular angle. Salgarelli et al., stated that malposition of the ear could be due to the lack of the development of the antihelix, an excessive dimension of the concha, an abnormal position of the auricle on the head or a sum of all these factors.

Aesthetic considerations are the most common indication for performing corrective surgery on the prominent ear. The stigma associated with protruding ears can negatively affects a child's psychological development, hence, children are the most common candidates for otoplasty, especially before the start of the child's elementary education and group socialization [7].

The procedure is best performed after the age of 4 to 6 years so that the child has appropriate maturity and insight to participate in the post-operative course. As patients age, it is important to remember that the cartilage will become more calcified and less malleable, such that predictable long term results may be more difficult to achieve

in adult patients. In the adult population, men often seek this operation more frequently than women, who are more likely able to camouflage their ears with longer hairstyles.

The desired postoperative results include, a normal appearing auricular contour from both the frontal and lateral views, an absence of unnatural sharp edges in the cartilage framework and achievement of symmetry of both ears. The techniques used must be relatively easy to learn and yield reproducible results [5].

The goals of otoplasty, as outlined by McDowell include, correction of protrusion, visibility of the helix and antihelix, smooth antihelical fold, undisturbed post-auricular sulcus, avoidance of a plastered down look and avoidance of a sharp antihelical fold [8,9].

PATIENTS AND METHODS

The present work included twenty patients with prominent ears who were presented and managed at Kasr Al-Aini Hospital (Cairo University) Department of Plastic Surgery, between 2013-2015. The age range was 2 to 6 years including sixteen males and four females. Cases have been divided into two equal groups, group 1 (10 cases) where surgical correction included concho-mastoid suture technique, while group 2 (10 cases) where surgical correction didn't include concho-mastoid suture technique. Group 2 was further subdivided into group 2A (5 cases), where correction was performed using prolene sutures, and group 2B (5 cases), where correction was performed using PDS sutures.

Preoperative photographs were taken, the ears were marked to outline the post-auricular incision. Prophylactic broad spectrum antibiotics were given to our patients during surgery to decrease the risk of chondritis. Preparation of the auditory canal with betadine was done. Surgical draping was performed while taking care of avoiding distortion of the ear, keeping the hair out of the field, and maximizing visibility of the ear. We used standard head drape with staples to hold the drape in place and allow full visualization of both the face and ears. All the surgeries were performed under general anesthesia.

An ellipse of skin was excised from the back of the ear, needles were inserted in the cartilage on the margins of the scapha, that is the area of concavity that separates the helical and antihelical folds. In group 1, a concho-mastoid prolene suture was performed. Scoring of cartilage was always done from the posterior surface of the ear and

along the inner aspect of the inserted needles. Suture correction was done just outside the zone of scoring using inverted prolene sutures in group A, and inverted PDS sutures in group B, then removal of the needles and closure of the wound using 4/0 interrupted monocryl sutures was performed. A head band was applied for 10 days. eighteen patients were followed up for 1 year and two patients were followed-up for 2 years.

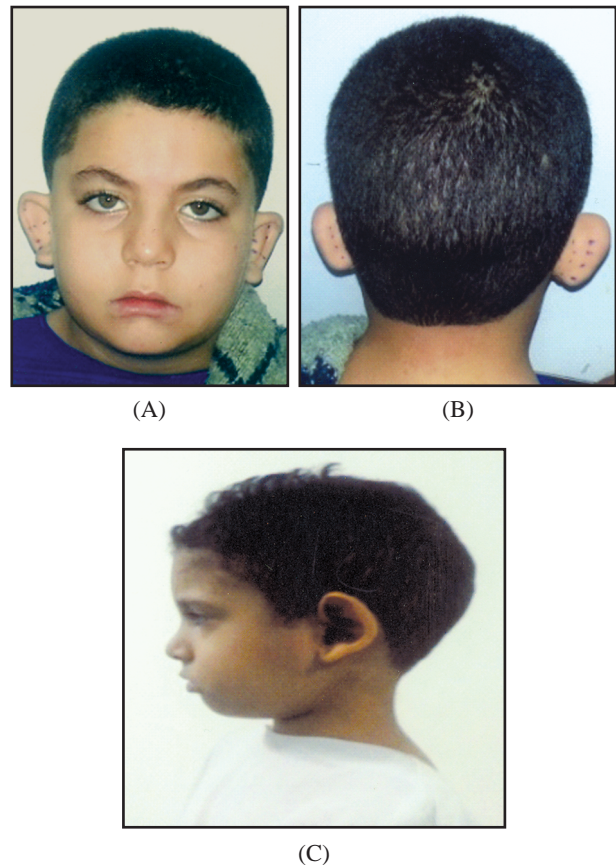


Fig. (1): Pre-operative photos of two patient with prominent ears; frontal and back view photos of a 6 years old patient (A,B) and a left side view photo of a 4 years old patient (C).

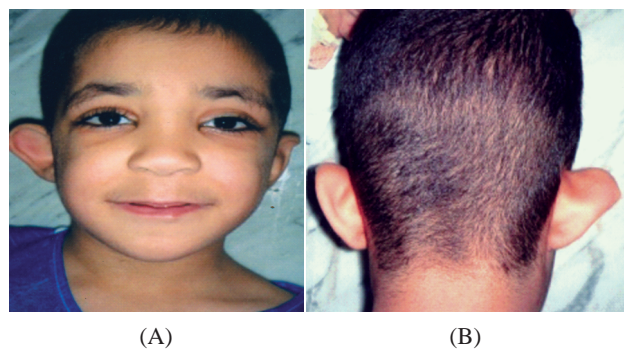


Fig. (2): Pre-operative view of a 5 years old patient with asymmetrical prominent ears, where the right ear is more prominent than the left ear.

RESULTS

Twenty patients were included in this study, sixteen males and four females. The mean age of the patients was four years. All the patients included in our study were children who had congenital bilateral prominent ears.

Assessment of the patient's outcome was done according to the following criteria; hematoma formation, wound breakdown, cartilage necrosis, suture complications (extrusion and granuloma formation), cosmetic results and recurrence.

Post-operative hematoma occurred in one patient in group 1, that is to say 10% of patients who performed concho-mastoid suture developed hematoma postoperatively. On the other hand, it did not occur in any patient in group 2.

Wound breakdown and cartilage necrosis occurred in one patient from group 2B (20%) where PDS sutures were used in the surgical correction, on the other hand it did not happen in any case where prolene sutures were used in the surgical correction.

Suture foreign body induced granuloma occurred in two patients from group 2A (40%) where prolene sutures were used in surgical correction, on the other hand it did not happen in any patient from group 2B where PDS sutures were used in the surgical correction.

Cosmetic disfigurement occurred in one patient in group 2B (20%), where PDS sutures were used in surgical correction, on the other hand it did not happen in any case from group 2A where prolene sutures were used in the surgical correction.

Recurrence occurred in one patient in group 2, and did not occur in any patient in group 1, where concho-mastoid suture technique was included in the surgical correction. two patients were followed-up for 2 years after surgery, we found no demonstrated visible disturbance in ear growth in these patients.

Table (1): Criteria of assessment of patient's outcome.

	Group 1	Group 2A	Group 2B
Hematoma	10%	—	—
Wound breakdown & cartilage necrosis	—	—	20%
Suture complications	—	40%	—
Cosmetic disfigurement	—	—	20%
Recurrence	—	5%	5%

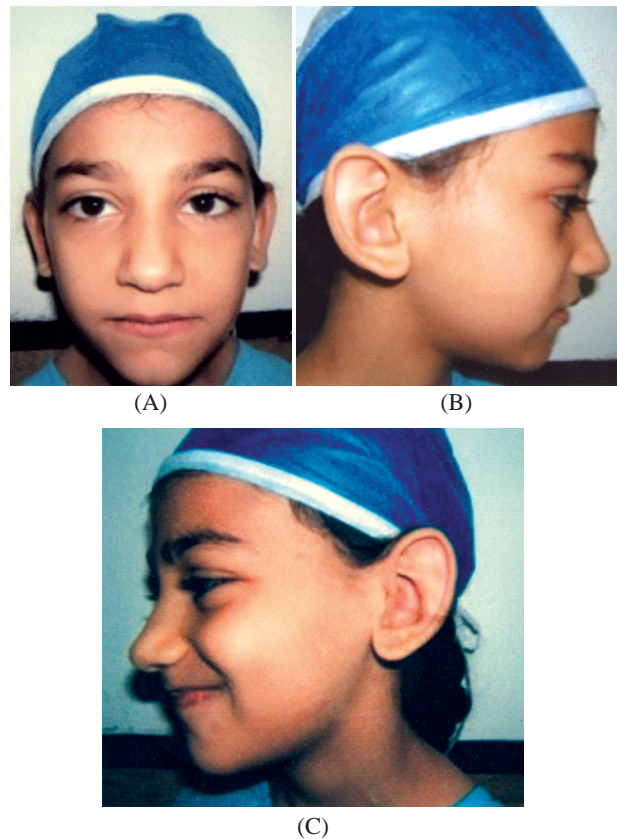


Fig. (3): Pre-operative photos of a six years old girl presenting with prominent ears.

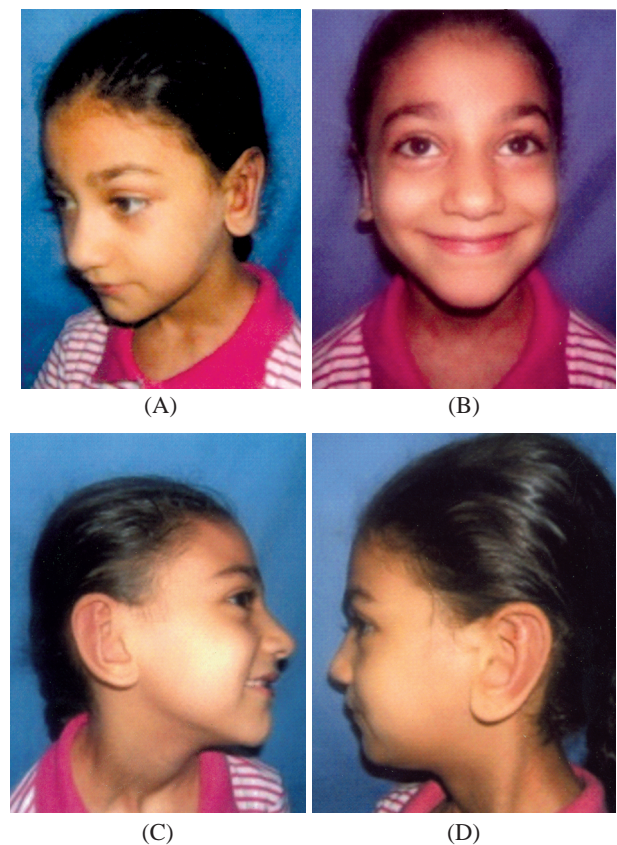


Fig. (4): Photos taken after four months of surgery of the same patient in Fig. (3).

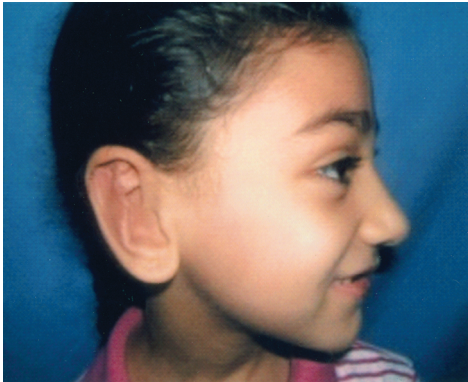

Fig. (5): A six months post-operative photo of the same patient in Fig. (3), showing some distortion in the configuration of the antihelical fold.

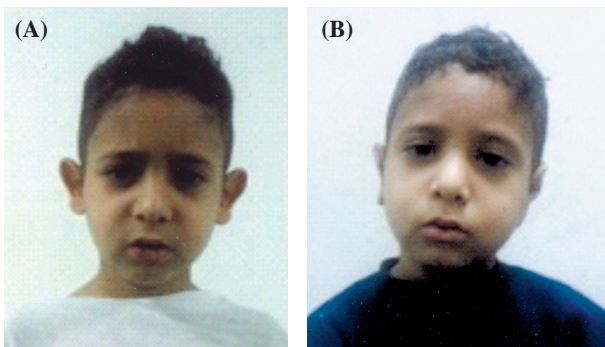


Fig. (6): Pre-operative photo (A), and post-operative photo (B) of a four years old patient with prominent ears; frontal view photos.

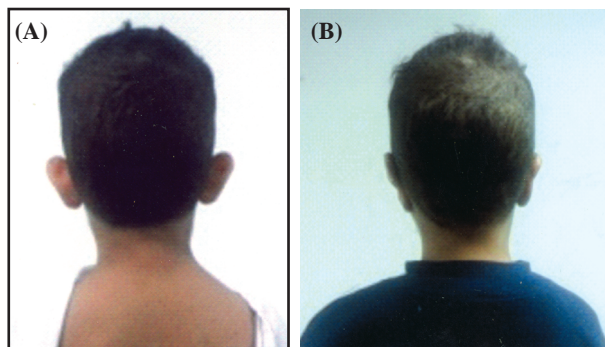


Fig. (7): Pre-operative photo (A), and post-operative photo (B) of the same patient in Fig. (6); back view photos.

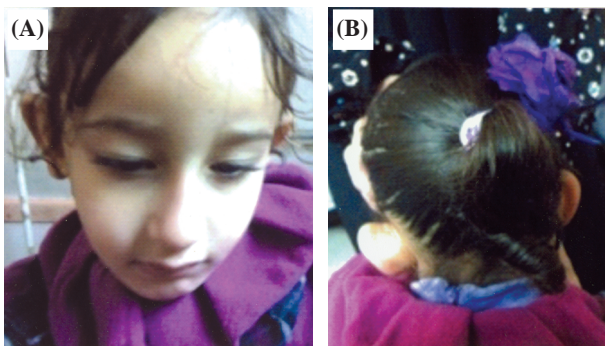

Fig. (8): Pre-operative photos, frontal view (A), and back view (B) of a five years old girl with prominent ears.

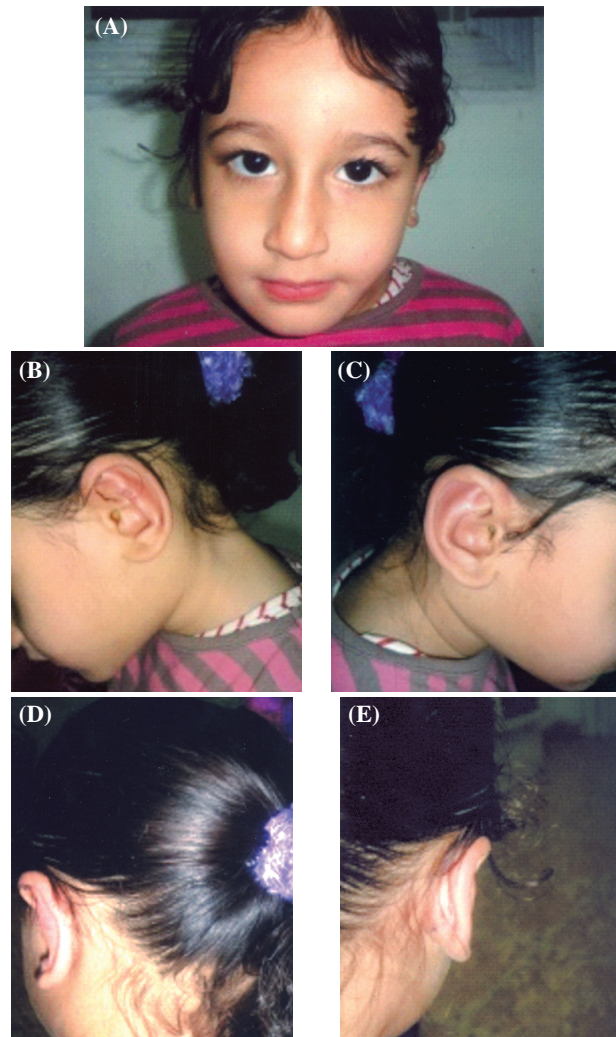


Fig. (9): Four months post-operative photos of the same patient in Fig. (8) after surgical correction which was done without using concho-mastoid suture.

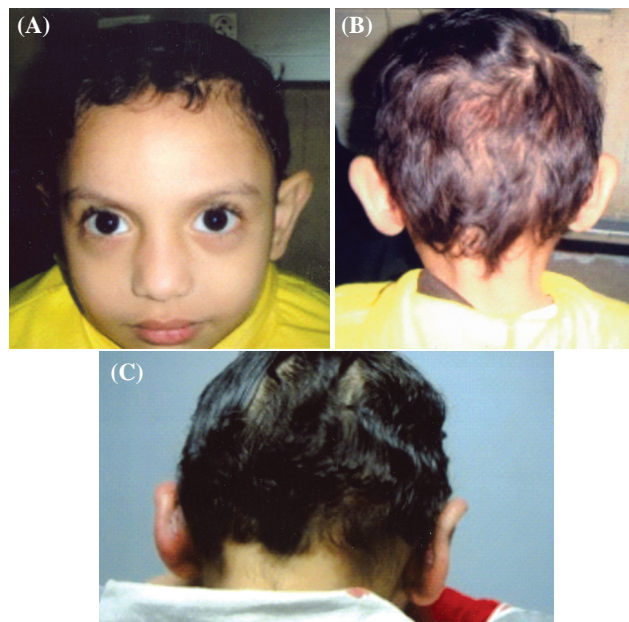


Fig. (10): Pre-operative photos of a three years old boy showing prominent ears.

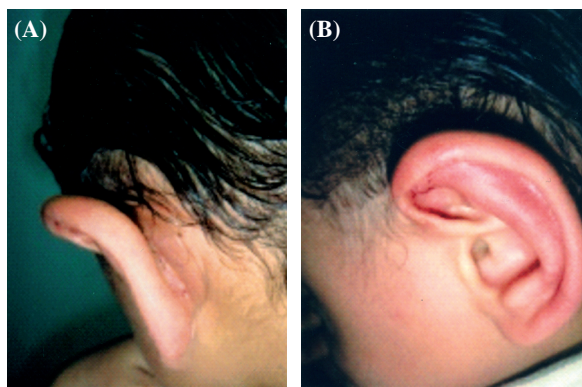


Fig. (11): Three weeks post-operative photos of the same patient in Fig. (10) after surgical correction done using concho-mastoid suture.

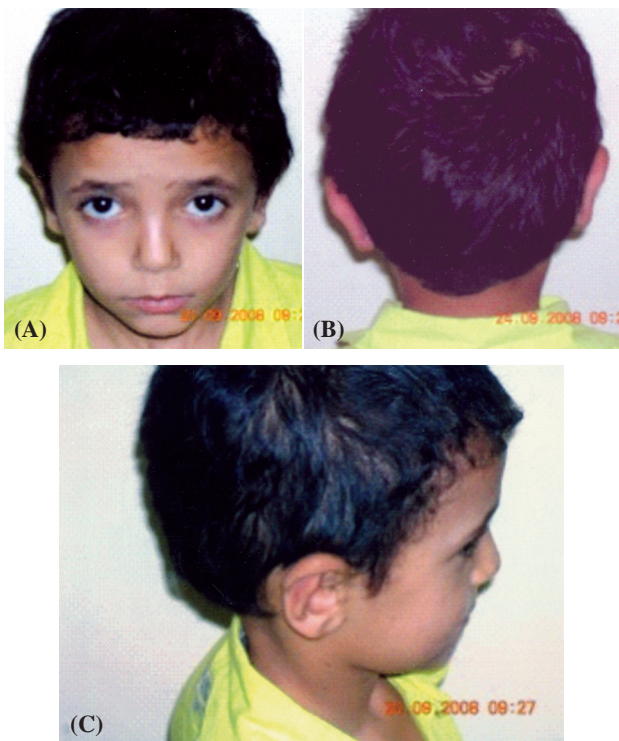

Fig. (12): Three years post-operative photos of the same patient in Figs. (10,11).

DISCUSSION

Children with protruding ears are often exposed to substantial psychological pressure. Numerous studies were focusing on the problems this deformity can impact on the children, like psychological distress, emotional trauma, behavioural problems, low self esteem, lack of self confidence and social isolation [10,11].

Our study reported an improvement in child's self confidence and this meets with found [11]. What Harlock et al. Hence it is recommended to perform

otoplasty in children suffering from protruding ears, prior to the start of schooling. Another important advantage of performing otoplasty at these young ages is the increased malleability and elasticity of the auricular cartilage, the softer the auricular cartilage, the easier is to shape the cartilage into the appropriate form using gentle surgical techniques, this meets what Songu and Adibelli stated [2].

According to our study, adding concho-mastoid suture to the surgical technique may decrease the risk of recurrence and increase the risk of postoperative hematoma formation. Using PDS sutures in the surgical repair may be more liable to increase the risk of wound breakdown, cartilage necrosis, cosmetic disfigurement and recurrence than using prolene sutures. On the other hand, using prolene sutures may be more liable to induce suture foreign body granuloma than using PDS sutures in the surgical repair.

In conclusion, the timing of surgery is an issue of concern with regard to otoplasty in children, given that the children often start preschool at the age of four years, there may be significant psychosocial benefits to early intervention, in addition no demonstrated visible disturbance in ear growth was observed. Our preference is to plan the otoplasty as young as 4 years of age, because after that age, the child starts to express concern about the deformity.

REFERENCES

- 1- Ellis D.A.F. and Keohane J.D.: A simplified approach to otoplasty. *J. Otolaryngol.*, 21: 66-69, 1992.
- 2- Songu M. and Adibelli H.: Otoplasty in children younger than 5 years of age. *International J. of Pediatric Otorhinolaryngology*, 74: 292-296, 2009.
- 3- Dieffenbach J.F.: *Die operative Chirurgie*. Leipzig, Germany, F.A. Brockhaus, 1845.
- 4- Potter E.I.: A hereditary ear malformation transmitted through five generations. *J. Heredity*, 28: 255, 1937.
- 5- Mobley S.R., Vartanian A.J. and Toriumi D.M.: Otoplasty: Surgical correction of the protruding ear. *Operative techniques in otolaryngology/Head & Neck Surgery*, 13: 29-35, 2002.
- 6- Adamson J.E., Horton C.E. and Crawford H.H.: Growth pattern of the external ear. *Plast. Reconstr. Surg.*, 36: 466-470, 1965.
- 7- Becker O.J.: Surgical correction of the abnormally protruding ear. *Arch. Otolaryngol.*, 50: 541-560, 1949.
- 8- McDowell A.J.: Goals in otoplasty for protruding ears. *Plast. Reconstr. Surg.*, 41: 17-27, 1968.

- 9- Bauer B.S.: Combined otoplasty technique: Analysis & treatment of the prominent ear. Operative techniques in Plast & Reconstrsurg, 4: 109-128, 1997.
- 10- Keery H., Boutelle K., Van Den Berg P. and Thompson J.K.: The impact of appearance-related teasing by family members, J. Adolesc. Health, 37 (2): 120-127, 2005.
- 11- Harlock N., Vogelien E., Bradbury E.T.: Psychosocial outcome of patients after ear reconstruction, A retrospective study of 62 patients, Ann. Plast. Surg., 54 (5): 517-524, 2005.